

THE EFFECTS OF ACOUSTIC FREQUENCIES ON CORE TENDON LESIONS OF THE THOROUGHBRED RACEHORSE

E.B. Bauer, K. Cooper, P. Jenks & A.H.J. Fleming, Biophotonics Research Institute, Malden, MA 02148

Abstract: The case study aimed to assess the effectiveness of an acoustic device on core tendon lesions of the thoroughbred race horse. Electromagnetic self-field theory (EMSFT) shows how the photon and the phonon have a similar sub-structure but an orthogonal orientation to each other. Hence sound, as well as EM exposure can interact to cause cellular effects within the cell-cycle such as replication or apoptosis. The therapeutic method involved the application of an acoustic device (Cyma 1000), which delivered specific frequencies, within the audible sound range, to acupuncture points and meridians as well as the areas of injury. These audible frequencies ranged from 100 to 1600 Hz. In our case studies, we have found a rapid rate of tendon healing; as evidenced by tendon healing with ultrasonographic imaging that clearly showed the return to normal and homogeneous tendon cell integrity as proven by the uniform and normal echogenicity. A complete reduction of the core lesions to a well defined tendon cell regeneration area with no evidence of prior tendon lesions was found. The mean duration of healing time, per follow-up ultrasonography, as well as the clinical signs of healing and rapid return to function was 40 days; from the first diagnostic ultrasound scan to the last follow-up ultrasound scan. The case studies demonstrated a significant improvement in pain and swelling, as well as objectively measurable functional improvements. Objective markers such as clinical improvement in ROM, function and return to work with no signs of lameness at the jog or the gallop. With the encouraging results of these case studies, further investigation of the efficacy of this acoustic device is warranted. The high quality of the homogeneous, healed, tendon tissue, per ultrasonographic evidence, translated into a low to null continued morbidity or threat of reinjury. The cost savings in veterinary diagnostics, care, treatment and maintenance over time, as well as the preservation in value of this athletic horse will further insure this horse owner a gainful return on their substantial financial investment.

Theoretical Considerations

Theory: EM self-field theory (EMSFT) [Fleming 2005] is an analytic solution to Maxwell's equations. Self-field theory (SFT) provides solutions applying to various physical phenomena including a generalization of Maxwell's equations suitable for the nucleus based on a photonic chemistry [Fleming and Colorio (nee Bauer) 2004a, 2004b]. Quantum field theory (QFT) and SFT taken together provide an enlarged vision of physics; both QFT and SFT are valid, producing similar but essentially different perspectives of the one physics. An analogy to QFT and SFT lies in the numerical techniques known as finite element method (FEM) and finite difference method (FDM). FEM uses Lagrangians involving integrations and FDM uses partial differential equations directly to solve systems of equations ; FDM is numerically and analytically simpler than FEM. Similarly, SFT applies solutions to the Maxwellian divergence equations into the remaining curl equations directly, rather than using Hamiltonians etc. SFT thus provides a basis for a unification across physics and biophysics.

EMSFT describes how EM interactions are fundamental to the workings of biological tissues. EMSFT shows how EM fields can be emitted from inside biological

systems whenever the fields within a protein or macromolecule change their eigenstates. Associated with the changes in these fields, structural changes can occur in hydration layers surrounding macromolecules such as DNA. EMSFT applies to the massive photon in the same way it applies to the hydrogen atom. The photon's transition frequencies are

expressed in terms of a continuous series, $\nu_{mn} = R_{ph} \left(\frac{1}{m^2} - \frac{1}{n^2} \right)$, where $m = 1, 2, 3, \dots$,

$n = 2, 3, 4, \dots$. The Rydberg number $R_{ph} = \frac{q_{ph}^4 m_{ph}}{8 \epsilon_0^2 h^3 c} = \frac{m_{ph} (8^2 \pi^3) \epsilon_0 v_o^2}{r_o q_{ph}^2}$ is a photon-specific

function of mass and charge. Shown in Figure 1, the photon has a continuous energy-frequency relationship since the photon's sub-particles have equal mass and opposite charge. Valid solutions can be obtained continuously across frequency ranges. The fields inside biological atoms, ions, and molecules thus have their own spectroscopic states in addition to the electrons and the nucleons.

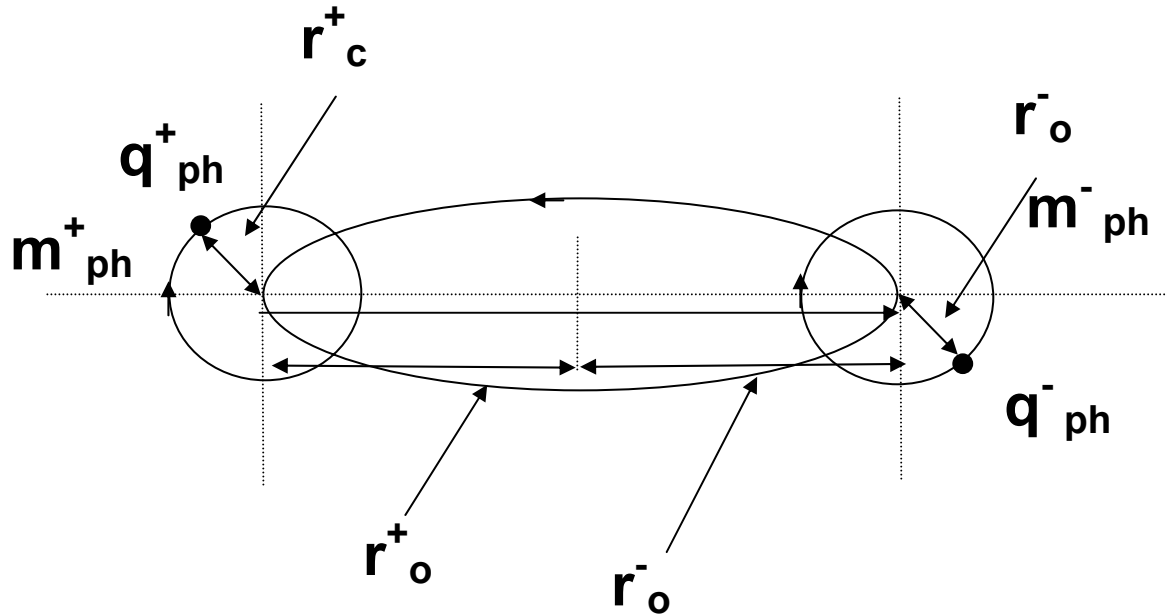


Figure 1. Photon sub-structure consists of two particles, the ephlectron, and the phroton, of equal mass $m_{ph} = m_{ph}^+ = m_{ph}^-$ and opposite charge $q_{ph} = q_{ph}^+ = -q_{ph}^-$. Each has two spinorial motions like the electron and proton in hydrogen atom.

Associated with changing energy levels across the cell cycle, there are structural changes originating within the fields of proteins such as the DNA that correspond to transition shifts in energy within each cell. Generally DNA can be controlled via delivery of energy of appropriate discrete frequencies involved in the cell cycle. One way to achieve this is via externally applied photons of precise frequency, i.e. EM radiation applied externally to any part of the body, in this case, to the tendons of thoroughbred horses. Another associated technique is to use acoustic energy instead of EM. In EMSFT, the photon and the phonon are theoretically shown to be two particles having the same

structure, but a different propagation vector. The phonon is orthogonal to the photon of equivalent energy. The phonon has the important advantage of being able to penetrate far deeper into biological tissues than EM radiation. Other acoustic interactions also occur inside atomic nuclei where gluons, photons, and phonons can interact. The various methods of energy delivery to either promote cell replication or cell apoptosis are generic to a wide class of medical therapies.

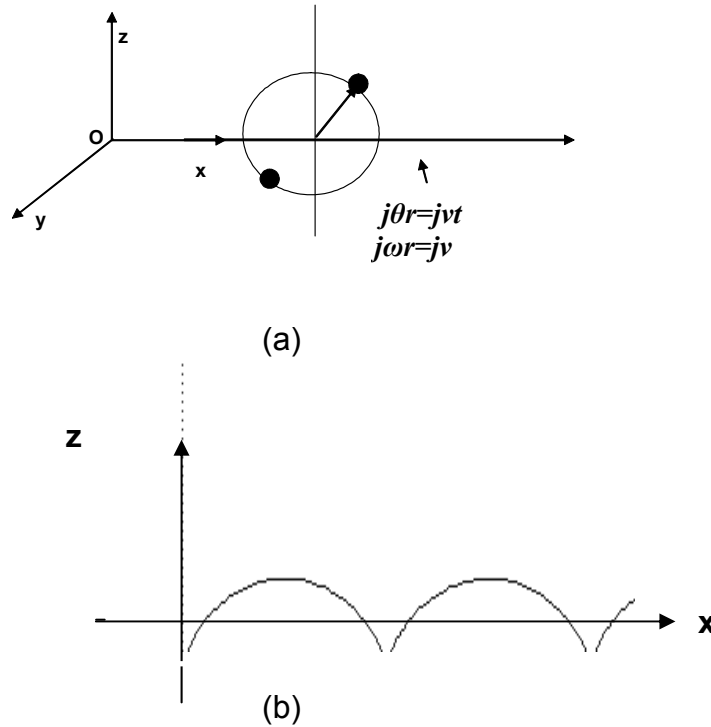


Figure 2. (a) Photon moves along the +X-axis performing internal rotations in XZ-plane (b) the photonic sub-particles perform cycloid motions. Where time is related to the internal rotations of the particle, its motion can be shown to be relativistic. As the velocity in X increases there will be a time and length dilation as given by the Lorentz transform.

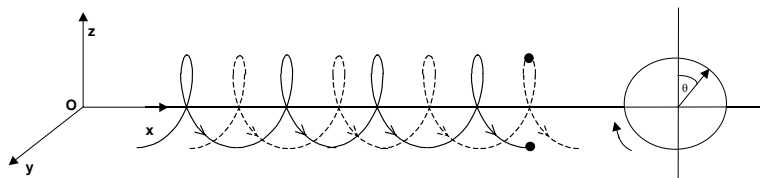


Figure 3. Phonon has same substructure as photon but its internal rotation is orthogonal to the direction of propagation. Its cross-section is much larger than a photon of equivalent energy and so its attenuation in free-space is far greater.

Intervention

The application of an acoustic device (Cyma 1000), which delivered specific frequencies, within the audible sound range, to acupuncture points and meridians as well as the areas of injury. These audible acoustic frequencies ranged from 100 to 1600 Hz.

Objective: To assess the effectiveness of an acoustic device on core tendon lesions of the thoroughbred race horse.

Outcome: In our case studies, we have found a rapid rate of tendon healing; evidenced by ultrasonographic imaging that clearly showed the return to normal and homogeneous tendon cell integrity as proven by the uniform and normal echogenicity. A complete reduction of the core lesions to a well defined tendon cell regeneration area with no evidence of a prior tendon lesion was found.

The mean duration of healing time, per follow-up ultrasonography, as well as rapid return to function was 40 days; from the first diagnostic ultrasound scan to the last follow-up ultrasound scan. All subjects, thus far, have had very similar results, therefore, only one complete case study will be presented here.

Primary Diagnostic Ultrasonographic Images

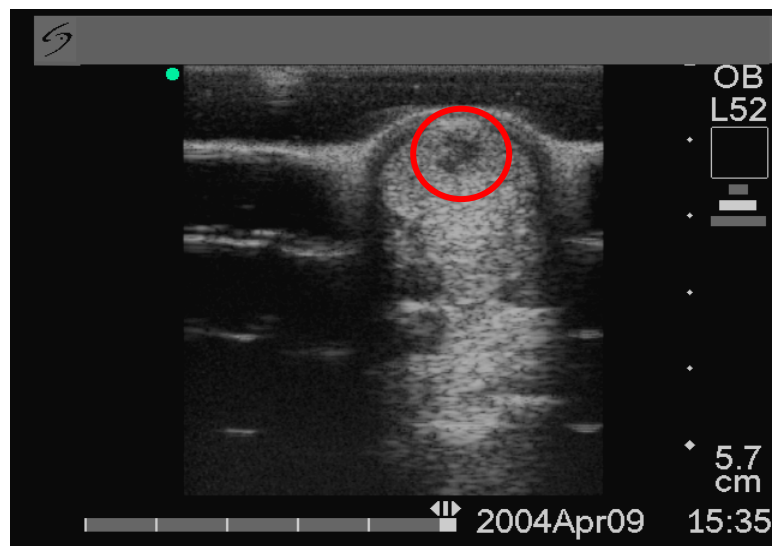


Image 1. Short axis ultrasonography of the SDFT 4-09-04

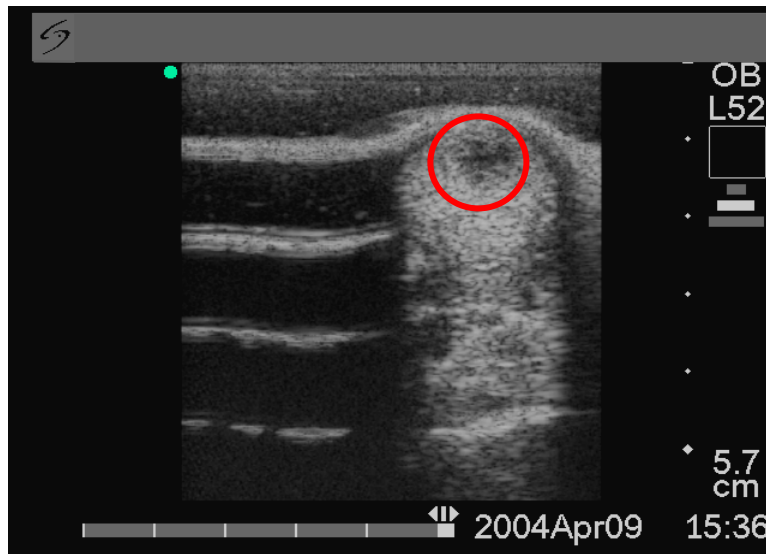


Image 2. Short axis ultrasonography of the SDFT 4-09-04

Ultrasound scan images during this primary clinical evaluation showed a very concise 25 to 30% core lesion of the superficial digital flexor tendon (SDFT).

First Follow-up Ultrasonographic Image

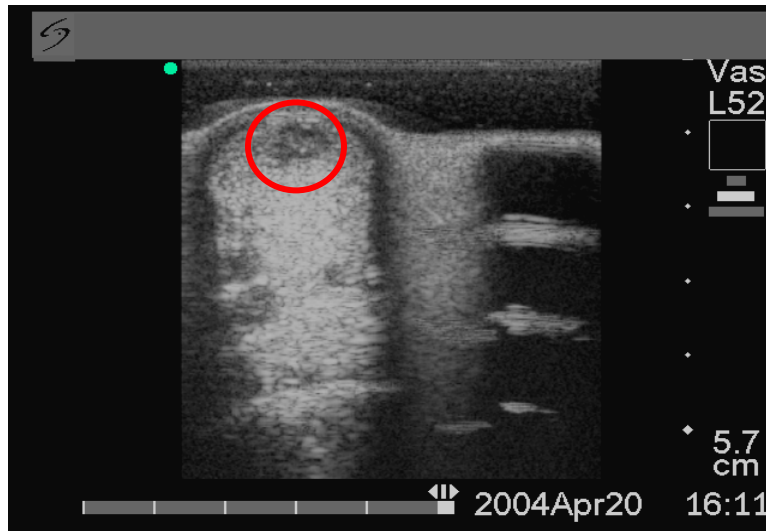


Image 3. Short axis ultrasonography of the SDFT 4-20-04

Clinical Evaluation

The first follow-up Ultrasound scan showed a 50% improvement in the SDFT core lesion size, with tendon cell density, fibrin deposition and collagen fibril formation as a clear indication of the hypoechoogenic healing of this SDFT tendon lesion.

Clinically, there was a decrease in lameness from a Grade 3.5 to Grade 2 of 5. There was decreased sensitivity to flexion and palpation of the flexor tendon in the left front limb. There was also a marked decrease in swelling and no more heat felt on palpation to the tendon area or the limb.

Second Follow-up Ultrasonographic Images

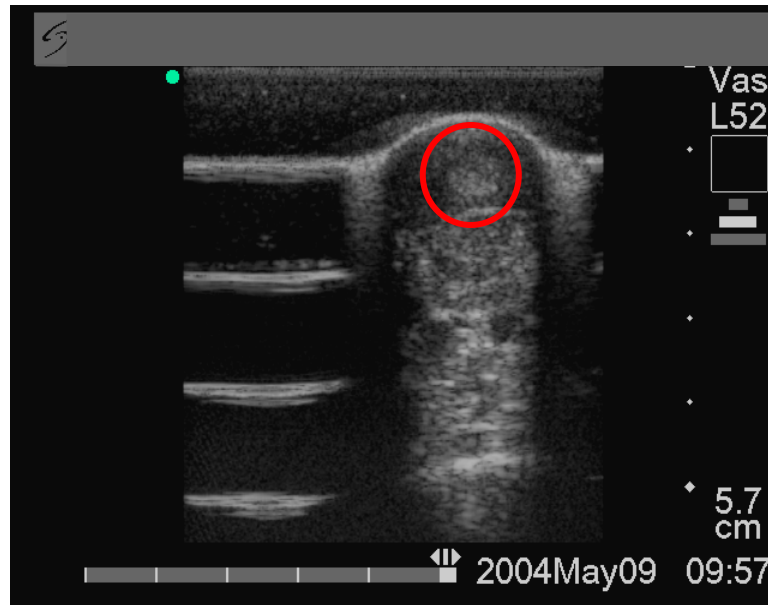


Image 4. Short axis ultrasonography of the SDFT 5-09-04

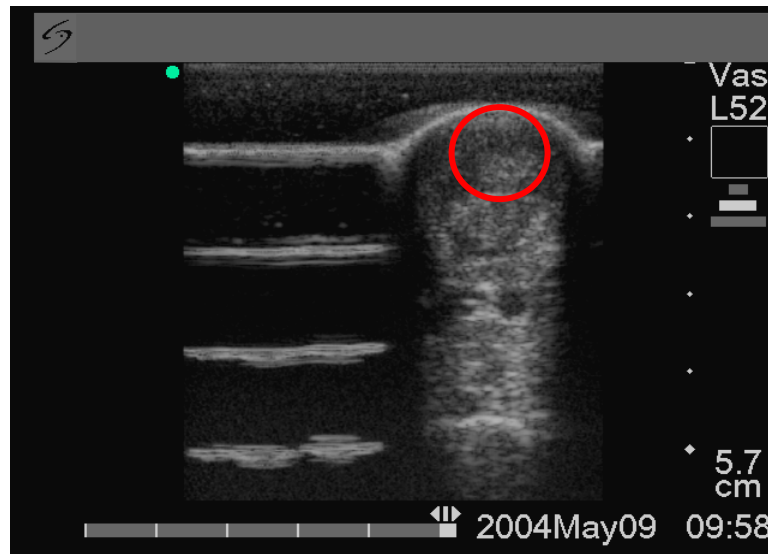


Image 5. Short axis ultrasonography of the SDFT 5-09-04

Clinical Evaluation

Ultrasound scan imaging showed a transition to a more uniform echogenicity with a complete reduction of the SDFT core lesion to a well defined tendon cell, fibrin and collagen filled area indicative of an accelerated healing process.

At this time clinical signs showed no lameness at the walk. There was no pain elicited during flexion or palpation. There was no visible swelling or heat felt during palpation.

Third Follow-up Ultrasonographic Images

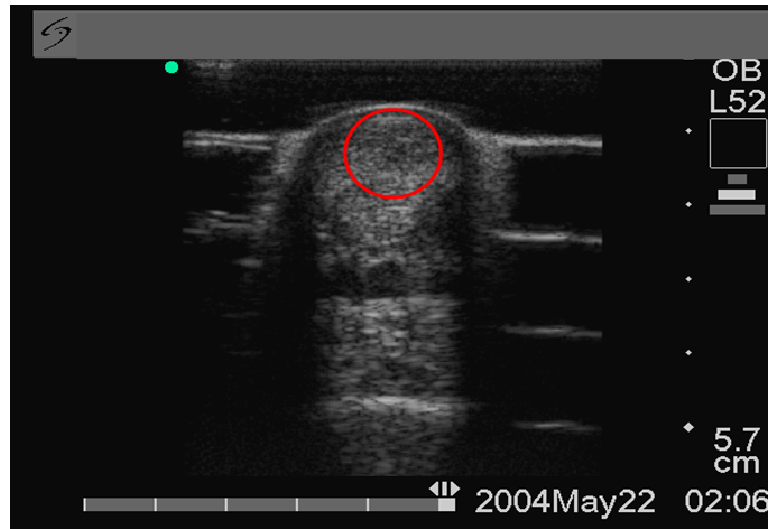


Image 6. Short axis ultrasonography of the SDFT 5-22-04

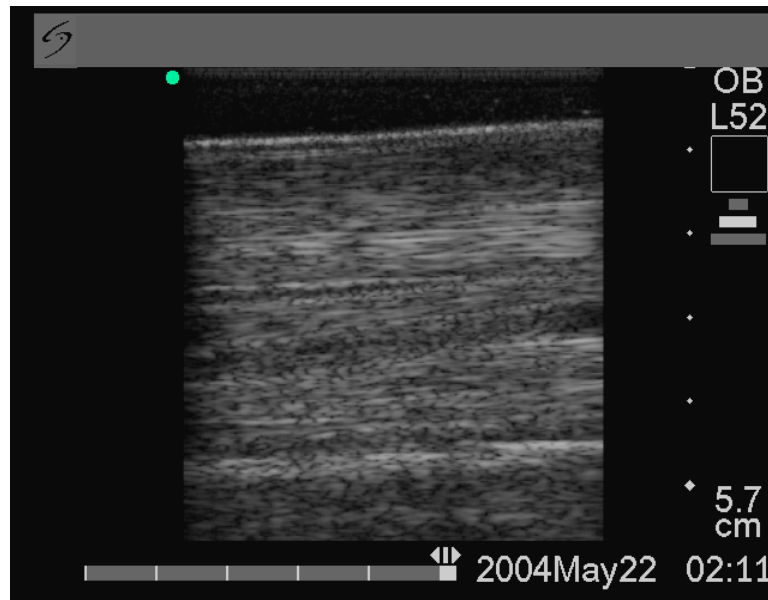


Image 7. Long axis ultrasonography of the SDFT 5-22-04

Clinical Evaluation

Image 6. Ultrasound scan showed a uniform and normal echogenicity with a complete reduction of the SDFT core lesion to a well defined tendon cell regeneration area with no evidence of a prior SDFT lesion.

Image 7. Ultrasound scan showed proper tendon cell and collagen fiber alignment with no further evidence of a prior SDFT core lesion.

At this time clinical signs showed no lameness at the jog or gallop. There was no pain elicited during flexion or palpation. There was no visible swelling or heat felt during palpation even after the increase in physical activity in the jog or gallop. There is no more evidence of lameness to date.

Discussion

The prognosis for return to use following injury to the SDFT in athletic horses has historically been graded fair to poor. According to the literature, the healing process can take from 6 to 24 months to occur and usually terminates with further evidence of disruption of normal fiber alignment and variable loss of echogenicity at the endpoint of study per follow-up ultrasonography.

Continued evidence of disruption of normal fiber alignment and variable loss of echogenicity are usually a result of adhesions and scar tissue that occur during the course of the healing process of an injured tendon. Any disruption, malalignment or change from the normal tendon cell alignment or consistency does predispose the horse to future reinjury; due to inconsistent load force and pressure distribution on impact, in the tissue surrounding the scared-in previous injury [Crevier-Denoix N et al 1997].

The high cost in veterinary diagnostics, care, treatment and maintenance, as well as the loss in value of the athletic horse is difficult to recuperate by the horse owner rendering the promising horse athlete a very high cost to maintain without gainful return. The high morbidity rate in the tendon injured horse, coupled with the continued threat of reinjury, translates into a substantial financial loss to the horse owner over time.

Conclusions

In this exemplary case study, we have found a rapid rate of tendon healing as well as tendon healing with the ultrasonographic evidence of the return to normal and homogeneous tendon cell integrity as proven by the uniform and normal echogenicity.

The duration of healing time, as evidenced by ultrasonography in this case study, as well as the clinical signs of healing and rapid return to function was 43 days; from the first diagnostic ultrasound scan on 4-09-04 to the last ultrasound scan on 5-22-04 to date.

This clearly shows that Equine Cyma Bioresonance treatments have surpassed any standard veterinary treatment of the SDFT injured horse by approximately 5 to 22.5 months ahead of any known standard treatments provided in the literature.

The high quality of the homogeneous, healed, tendon tissue, per ultrasonographic evidence, translated into a low to null continued morbidity or threat of reinjury.

The cost savings in veterinary diagnostics, care, treatment and maintenance over time, as well as the preservation in value of this athletic horse will further insure this horse owner a gainful return on their substantial financial investment.

Evaluation

These case studies demonstrated a significant improvement in pain and swelling, as well as objectively measurable functional improvements. Objective markers such as clinical improvement in ROM, function and return to work with no signs of lameness at the jog or the gallop.

With the encouraging results of these case studies, further investigation of the efficacy of this acoustic device is warranted.

References

A.H.J. Fleming, “*Electromagnetic self-field theory and its application to the hydrogen atom*”, Physics Essays, accepted for publication May 2005. <http://www.unifiedphysics.com>

A.H.J. Fleming and E.B. Colorio, “*Prediction of a photonic chemistry*”, 26th annual meeting of BEMS, Washington, June 20-24, 2004a. <http://www.unifiedphysics.com>

A.H.J. Fleming and E.B. Colorio, “*The spectroscopy of the EM field*”, 3rd International Workshop on Biological effects of EMFs, Kos, 4-8 October 2004b.

Fleming A.H.J., Colorio E.B, “*The Photon and its energy*”, Biophotonics Research Institute; 2003. <http://www.biophotonicsresearchinstitute.com>

Crevier-Denoix N. et al. *Mechanical properties of pathological equine superficial digital flexor tendons*. Equine Vet J Suppl 1997 May;(23):23-6

Goodship A.E. *The pathophysiology of flexor tendon injury in the horse*. Equine Vet Educ 1993;5:23-29.

Further information on SFT may be obtained at <http://www.unifiedphysics.com>

Further information on the Cyma 1000 may be obtained at <http://www.cymatherapy.com>